

Bone Reconstruction of the Humeral Shaft after Carcinologic Excision Using a Fibular Bone Graft. (A Case Report)

**Z. F. Zengui^{1*}, M. Sennouni¹, M. Fargouch¹, Y. El Andaloussi¹, A. R. Haddoun¹
and D. Bennouna, M. Fadili¹**

¹*Department of Traumatology and Orthopedics Wing 4, CH Ibn Rochd, Casablanca, Morocco.*

Authors' contributions

This work was carried out in collaboration among all authors. All authors read and approved the final manuscript.

Article Information

Editor(s):

(1) Parth Trivedi, C.M. Patel College of Physiotherapy, Civil Hospital Campus, India.

Reviewers:

(1) Shane McCrea, England.

(2) Rasha Mamdouh Ahmed Salama, Menoufia University, Egypt.

Complete Peer review History: <https://www.sdiarticle4.com/review-history/72657>

Received 15 June 2021

Accepted 21 August 2021

Published 26 August 2021

Case Study

ABSTRACT

The free fibular bone graft constitutes one of the surgical options in the filling of the loss of bone substances after tumor resection on long bones in young patients followed for cancer with single or multiple metastasis. The lack of vascular supply of fibular grafts could be one of the non-union factors that characterize the failures observed after their placement in bone reconstructions of more than 6 cm. We report in our observation the limits of the non-vascularized fibular bone graft after excision and bone reconstruction of a loss of substance in the treatment of a pathological fracture of the humerus in a 47-year-old patient followed for mammary carcinoma; and also insisting on the urgent need to perform a biopsy for any lesions suspected of metastasis in a patient followed for cancer so as not to overlook a benign or malignant tumor which may turn out to be more aggressive than the known tumor.

Keywords: Bone reconstruction; fibular; bone metastases; bone scintigraphy.

*Corresponding author: Email: zifazengui@gmail.com;

1. INTRODUCTION

Vascularized bone transfers or not are indicated in front of any loss of bone substance whether it is of traumatic origin or following a tumor resection [1–5]. The fibular graft technique is therefore part of the therapeutic arsenal of reconstructions of loss of bone substance after tumor resection [6–11]. It can be used in different forms, which makes it possible to adapt the loss of substance to be reconstructed [5,12]. We report our experience concerning a fibular bone transfer after excision of a metastatic pathological fracture of the humeral shaft in a 47-year-old patient followed for breast carcinoma.

2. CLINICAL CASE

47-year-old patient, followed for a mammary carcinoma of the left breast with single bone metastasis at the level of the left humeral shaft diagnosed in 2010 for which she underwent 06 chemotherapy sessions and 08 neoadjuvant radiotherapy sessions and a mastectomy according to Patey had been performed in September 2010 associated with 06 adjuvant radiotherapy sessions, and the biological assessment, in particular the dosage of the medium 15-3 carbohydrate antigen was 21U / ml in 5 years, allowing us to conclude that cancer had cured in 2015. It was sent to us in the emergency room in March 2017, for a closed

trauma to the left arm following a fall in height without a vascular-nervous deficit.

The radiography of the left arm from the front and profile revealed an osteolytic image at the 1/3 proximal and middle union of the left humeral shaft, poorly limited, mitotic, blowing the external cortex with a rupture of the internal cortex, without invasion soft parts; suggesting a pathological fracture of the left humerus (Fig. 1).

The extension assessment, carried out in particular, is a bone scan highlighted an absence of bone anomaly outside the known and fractured left humeral focus; and the thoraco-abdomino-pelvic proton emission tomography noted a hypermetabolic pleural thickening opposite the basal segment of lobe V of the left lung, two non-hypermetabolic centimetric and infracentimetric nodules of the lungs.

The CA 15-3 and the rest of the biological balance achieved were normal.

A lung surgical biopsy was in favor of a single sclerosing pneumocystoma with chronic fibro-inflammatory rearrangement with crushed foci and without carcinomatous proliferation on the material, and the immunohistochemistry study showed that the cells mostly expressed cytokeratin 7 and TTF- 1. The GCDF15 was negative.

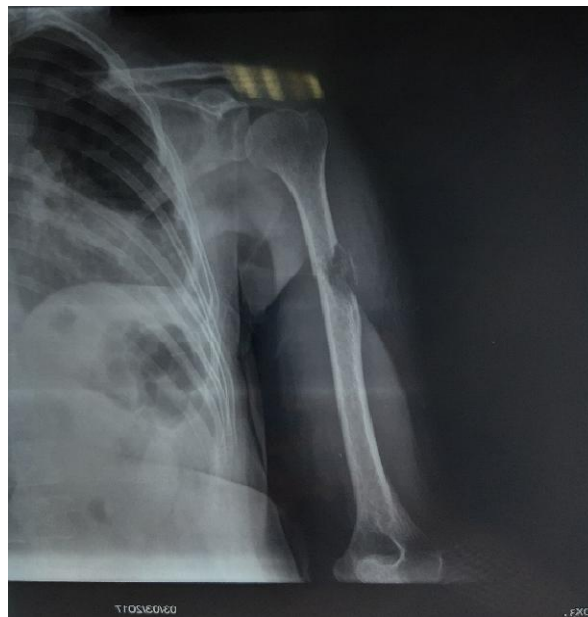


Fig. 1. Osteolytic image at the 1/3 proximal and middle union of the left humeral shaft, poorly defined, mismatched with a rupture of the internal cortex

The indication of a surgical assumption had been posed, and the intervention was carried out under general anesthesia, by antero-external approach of the arm first with an extension in deltopectoral to the proximal part, then resection to 4 cm above the mass and 7cm below thus allowing the ablation in block of the mass and the surrounding soft parts.

Secondly, reconstruction of the loss of humeral substance was carried out by placing a free 15 cm long fibular graft which was embedded at the level of the humeral fragments and stabilized by a locked plate at the proximal end of the humerus (Figs. 2 and 3).

The anatomico-pathological examination of the operative specimen concluded in a grade III SBR invasive poorly differentiated breast carcinoma with muscle and bone involvement, and the muscle and bone boundaries at the sectional

level were healthy. The study of hormone receptors: estrogen receptors (clone 1D5 DAKO), progesterone (clone PgR636 DAKO) and Ki 67 was positive; with an absence of expression of tumor cells and a Status Her 2 / Neu score of zero. The patient put on hormone therapy containing anastrozole at a rate of 1 mg per day.

At the 3-year follow-up, we noted the patient in a good general condition and reduction of joint amplitudes without impact on daily activities; with an MSTS score which was rated 80%. Radiologically, a fibular graft was well placed with precarious integration of the fibular graft at the level of the proximal part and the distal part (Fig. 5). The 3-year follow-up scintigraphy revealed heterogeneous fixation of the left humerus with the presence of a hyperfixing and heterogeneous sub-capital focus (Fig. 6).

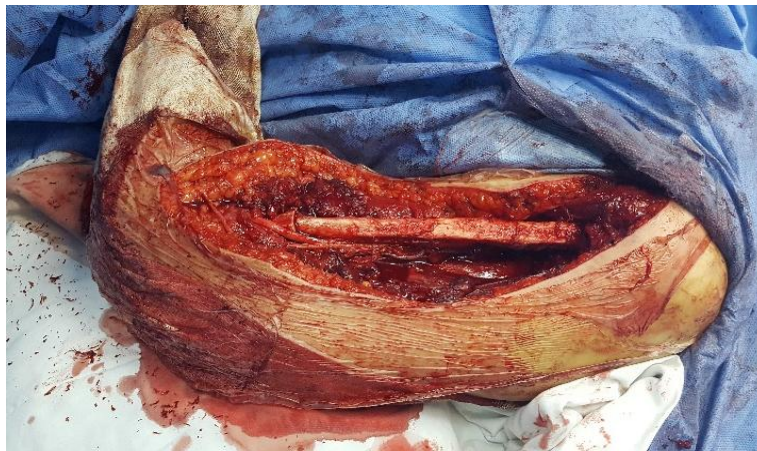

Fig. 2. 15 cm free fibular graft embedded in the proximal and distal fragment of the humerus

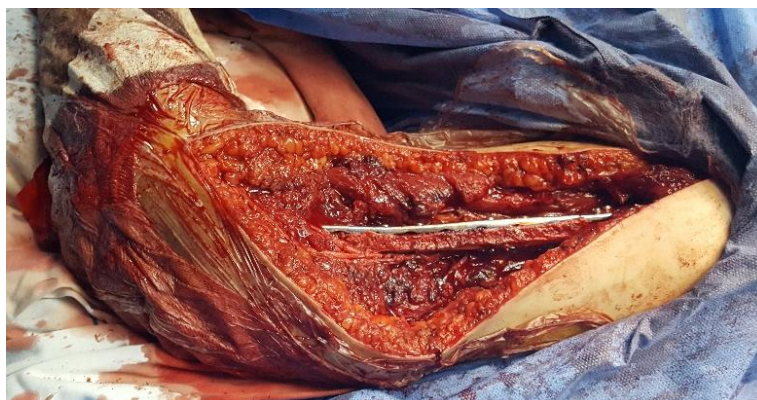


Fig. 3. Free fibular graft stabilized by an anatomical LCP plate from the proximal end of the humerus

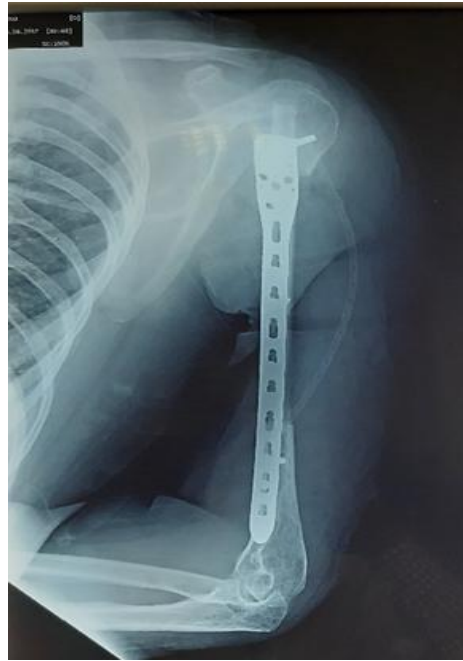

Fig. 4. Post-operative radiograph showing the fibular graft stabilized by a locked plate

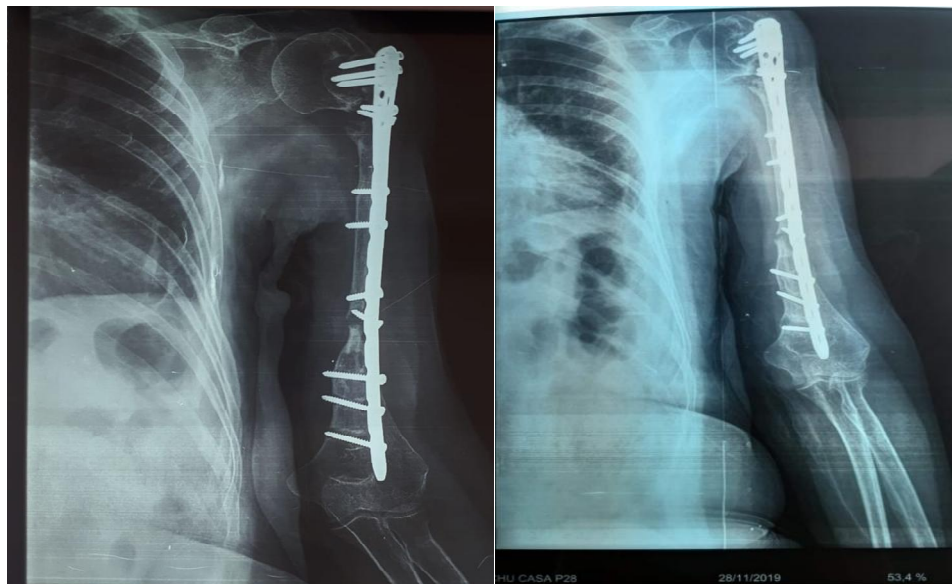


Fig. 5. Frontal X-ray after 30 months of follow-up showing the fibular graft well in place with precarious union proximally and distally

3. DISCUSSION

Metastatic involvement of the skeleton is a common cause of morbidity in cancer patients with bone pain, pathological fracture or compression of the spinal cord [13,14]. A number of bone metastases can be discovered during an

extension workup or occur during the follow-up of a known cancer and in this case pose few diagnostic problems. Metastatic involvement in the humerus often involves the proximal end of the humerus rather than the diaphyseal part [2,11,15].

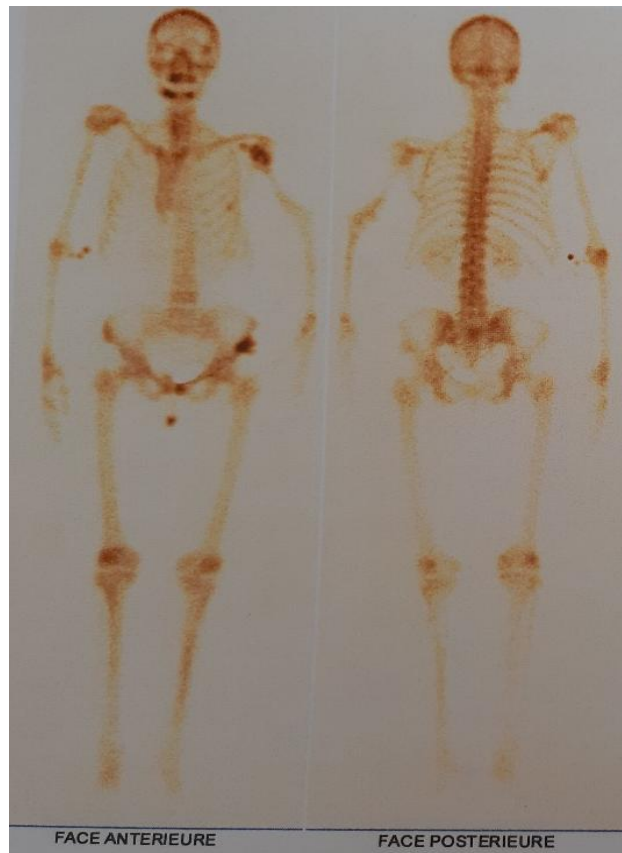


Fig. 6. Bone scintigraphy, at 3 years of follow-up, noted hyperfixation at the proximal part between graft and proximal fragment

In patients followed for breast cancer, metastatic bone damage represents more than 60% and its involvement on long bones is 4 -12% and M. Katzner, and al found, in a study of 300 cases of bone metastases, 6% of metastases at the level of the humeral shaft [16,17].

Several therapeutic options for surgical reconstruction can be used: free fibular bone graft, allografts, vascularized fibular grafts and combinations of allografts associated with bone fibular graft or the induced membrane technique. All these resection and reconstruction techniques must achieve margins for oncological resection, thereby improving the final result [18–25].

The choice between the vascularized fibular graft and the free fibular graft depends as much on the choice of the surgeon as on the particular characteristics of each patient [20,26,27].

Several authors nevertheless underline favorable results in vascularized fibular grafts, with a shorter time to union in vascularized grafts [28].

In our observation, we noted a non-union of the fibular graft, particularly at its distal end, and continuity and mechanical resistance were then only ensured by the LCP plate [1]. The use of a non-vascularized graft would be incriminated, in the literature, as one of the causes of non-union of the graft, due to an absence of biological activity that the vessels bring to the level of the union site.

Estrella and al, in a comparison between the vascularized fibular graft and not, noted a higher union rate was achieved using free vascularized fibular flaps compared to non-vascularized fibular grafts for a long bone reconstruction after tumor excision but without significant difference on the MSTS Score between the two groups, and concluded that a free vascularized fibular flap was four times more likely to unite compared to non-vascularized fibular grafts [23].

Liu S and al, in a study using both types of graft, noted a union rate for all patients was 100% but

the average union time was 21.3 weeks for vascularized fibular grafts and 30.5 weeks for non-vascularized fibular grafts ($P = 0.310$); with the only advantage for vascularized fibular grafts is graft hypertrophy [21].

This graft hypertrophy was observed in the series by Shi LL and al, at the start of the postoperative period, which reached a plateau with time. The vascularized fibular graft is an attractive option because of the ability of the graft to hypertrophy. This option is of particular interest in bone reconstruction in the adolescent and pediatric population, in which long-term viability and mechanical stability are required for successful recovery of limb function [15,21].

Allsopp and al, pointed out that a vascular supply was useful when large fibular bone fragments were used, especially those over 6 cm in length for long bone reconstructions. However, there is little scientific data to confirm this hypothesis; and this 6cm rule remains controversial to this day for several authors [20].

The Capanna procedure could be an alternative technique to the reconstruction of large bone defects [28]. This surgical approach combines the mechanical strength of the autograft with the biological activity of the allogeneic transplant to improve bone healing, thereby minimizing autograft failures. However, this technique finds little place in reconstruction after resection of a malignant humeral tumor [25,26].

Likewise, the Masquelet technique would be a reliable option after bone tumor resection but requires two-stage surgery; and parceled autologous spongy graft is not recommended when the loss of substance exceeds 4 to 5 cm; beyond 5 cm; consolidation is incomplete, due to resorption of the autograft even in a well-vascularized muscle environment [24].

In our observation, we could note the contribution of bone scintigraphy in comparison with radiological images and the clinic. On standard radiographs, we suspected a nonunion of the graft distally, while the scintigraphy just reported hyperfixation at the proximal level which would be related either to the bone callus or the presence of the osteosynthesis material, or to the suspicion of a recidivism. Bone scintigraphy seems to provide more precision on the survival or not of the graft, but not necessarily the union of an autograft. Additional monitoring techniques should be used in combination with a single bone

scan to monitor both risk of recurrence and graft survival [29].

An anatomopathological examination of the pulmonary lesions discovered during the extension assessment had made it possible to isolate a sclerosing pneumocytoma in our patient followed for known breast cancer. This rare benign lung tumor presents a diagnostic challenge due to the diversity of histological findings. Sclerosing pneumocytoma is a strictly histologic diagnosis supported by the corresponding immunohistochemical methods with cells mostly expressed cytokeratin 7, and TTF-1. GCDF15 was negative as noted in the biopsy of our observation. This entity could constitute an important diagnostic trap, especially in patients followed for cancer [30].

4. CONCLUSION

The use of a free fibular graft for the reconstruction of bone defects is an option in reconstructive surgery but may be associated with a high rate of graft non-union. The fibular graft vascularized by the vascular supply provides at the site and its hypertrophied character seems to be ideal in reconstructions of more than 6cm. Performing a biopsy for any lesions suspected of metastasis in a patient followed for cancer should be imperative in order not to overlook a benign or malignant tumor which may turn out to be more aggressive than the known tumor.

CONSENT

It is not applicable.

ETHICAL APPROVAL

It is not applicable.

COMPETING INTERESTS

Authors have declared that no competing interests exist.

REFERENCES

1. Chen H, Ji X, Gao Y, Zhang L, Zhang Q, Liang X, et al. Comparison of intramedullary fibular allograft with locking compression plate versus shoulder hemiarthroplasty for repair of osteoporotic four-part proximal humerus fracture: Consecutive, prospective, controlled, and

- comparative study. *Orthop Traumatol Surg Res.* 2016;102(3):287-92.
2. Wright TW, Miller GJ, Vander Griend RA, Wheeler D, Dell PC. Reconstruction of the humerus with an intramedullary fibular graft. A clinical and biomechanical study. *J Bone Joint Surg Br.* 1993;75(5): 804-7.
 3. Xiao N, Zhang L, Peng X, Mao C, Zhang J, Cai ZG. Non-vascularised fibular bone graft after vascular crisis: Compensation for the failure of vascularised fibular free flaps. *Br J Oral Maxillofac Surg.* 2018; 56(8):667-70.
 4. Paniel M, Petit P, Jouve JL, Portier F, Legré R, Bourlière B, et al. Imaging of vascularized fibular grafts in large bone reconstruction in skeletally immature patients. *Skeletal Radiol.* 1997;26(7): 404-8.
 5. Sadove RC, Burgess RC. Immediate reconstruction of bone and skin defects of the humerus with free fibular graft and muscle flap. *J Ky Med Assoc.* juin. 1990;88(6):295-8.
 6. Murray PM. Free vascularized bone transfer in limb salvage surgery of the upper extremity. *Hand Clin.* 2004; 20(2):vi,203-11.
 7. Germain MA, Dubousset J, Mascard E, Missenard G, Kalifa C. [Reconstruction of the long bones of the legs in children via free vascularized transplant of the fibula after resection for sarcoma]. *Bull Acad Natl Med.* 1996;180(5):1125-41, discussion 1141-1145.
 8. Cosker T, Gibbons CLMH. Surgical management of primary bone sarcomas. *Orthopaedics and Trauma.* 2017;31(3):173-9.
 9. Heitmann C, Erdmann D, Levin LS. Treatment of segmental defects of the humerus with an osteoseptocutaneous fibular transplant. *J Bone Joint Surg Am.* 2002;84(12):2216-23.
 10. Belt PJ, Dickinson IC, Theile DRB. Vascularised free fibular flap in bone resection and reconstruction. *Br J Plast Surg.* 2005;58(4):425-30.
 11. Kumta SM, Leung PC, Yip K, Hung LK, Panozzo A, Kew J. Vascularized bone grafts in the treatment of juxta-articular giant-cell tumors of the bone. *J Reconstr Microsurg.* 1998;14(3):185-90.
 12. Taylor J, Kumar A. Surgical management of skeletal metastases of the appendicular skeleton. *Orthopaedics and Trauma.* 2017; 31(3):188-94.
 13. Cirstoiu C, Cretu B, Serban B, Panti Z, Nica M. Current review of surgical management options for extremity bone sarcomas. *EFORT Open Rev.* 2019;4(5): 174-82.
 14. Wang W, Yeung KWK. Bone grafts and biomaterials substitutes for bone defect repair: A review. *Bioact Mater.* 2017;2(4): 224-47.
 15. Shi LL, Garg R, Jawa A, Wang Q, Chai Y, Zeng B, et al. Bony Hypertrophy in Vascularized Fibular Grafts. *Hand (N Y).* 2020;1558944719895784.
 16. Houdek MT, Wagner ER, Wyles CC, Nanos GP, Moran SL. New options for vascularized bone reconstruction in the upper extremity. *Semin Plast Surg.* 2015; 29(1):20-9.
 17. Katzner M, Babin SR, Schvingt E. Bilan de 20 ans d'ostéosynthèse des métastases osseuses. *International Orthopaedics.* 1985;9(2):89-96.
 18. Cirstoiu C, Cretu B, Serban B, Panti Z, Nica M. Current review of surgical management options for extremity bone sarcomas. *EFORT Open Rev.* 2019;4(5):174-82.
 19. Emori M, Kaya M, Irifune H, Takahashi N, Shimizu J, Mizushima E, et al. Vascularised fibular grafts for reconstruction of extremity bone defects after resection of bone and soft-tissue tumours: A single institutional study of 49 patients. *Bone Joint J.* 2017;99-B(9): 1237-43.
 20. Allsopp BJ, Hunter-Smith DJ, Rozen WM. Vascularized versus Nonvascularized Bone Grafts: What Is the Evidence? *Clin Orthop Relat Res.* 2016;474(5):1319-27.
 21. Liu S, Tao S, Tan J, Hu X, Liu H, Li Z. Long-term follow-up of fibular graft for the reconstruction of bone defects. *Medicine (Baltimore).* 2018;97(40):e12605.
 22. Imran Y, Zulmi W, Halim AS. Early complication following long bone reconstruction using vascularised fibula graft. *Med J Malaysia.* 2004;59 Suppl F:35-8.
 23. Estrella EP, Wang EHM. A Comparison of Vascularized Free Fibular Flaps and Nonvascularized Fibular Grafts for Reconstruction of Long Bone Defects after Tumor Resection. *J Reconstr Microsurg.* 2017;33(3):194-205.

24. Masquelet AC. La technique de la membrane induite dans les reconstructions osseuses segmentaires: Développement et perspectives. Bulletin de l'Académie Nationale de Médecine. 2017;201(1): 439-53.
25. Capanna R, Bufalini C, Campanacci M. A new technique for reconstructions of large metadiaphyseal bone defects. Orthop Traumatol. 1993;2:159–161.
26. Zekry KM, Yamamoto N, Hayashi K, Takeuchi A, Alkhooly AZA, Abd-Elfattah AS, et al. Reconstruction of intercalary bone defect after resection of malignant bone tumor. J Orthop Surg (Hong Kong). 2019;27(1): 2309499019832970.
27. Houdek MT, Bayne CO, Bishop AT, Shin AY. The outcome and complications of vascularised fibular grafts. Bone Joint J. 2017;99-B(1):134-8.
28. Li J, Wang Z, Pei G-X, Guo Z. Biological reconstruction using massive bone allograft with intramedullary vascularized fibular flap after intercalary resection of humeral malignancy. J Surg Oncol. 2011;104(3):244-9.
29. Greenberg BM, Jupiter JB, McKusick K, May JW. Correlation of postoperative bone scintigraphy with healing of vascularized fibula transfer: A clinical study. Ann Plast Surg. 1989;23(2):147-54.
30. Lovrenski A, Vasilijević M, Panjković M, Tegeltija D, Vučković D, Baroš I, et al. Sclerosing Pneumocytoma: A Ten-Year Experience at a Western Balkan University Hospital. Medicina (Kaunas). 2019;55(2).

© 2021 Zengui et al.; This is an Open Access article distributed under the terms of the Creative Commons Attribution License (<http://creativecommons.org/licenses/by/4.0>), which permits unrestricted use, distribution, and reproduction in any medium, provided the original work is properly cited.

Peer-review history:

*The peer review history for this paper can be accessed here:
<https://www.sdiarticle4.com/review-history/72657>*