



## **Cerebellar Blastomycosis in an Immunocompetent Patient: A Case Report**

**K. Agyen-Mensah<sup>1,2,3\*</sup> and H. Akoto<sup>4</sup>**

<sup>1</sup>Department of Neurosurgery, Stellenbosch University, South Africa.

<sup>2</sup>School of Medical Sciences, K.N.U.S.T, Ghana.

<sup>3</sup>Department of Surgery, Cape Coast Teaching Hospital, School of Medical Sciences,  
University of Cape Coast, Ghana.

<sup>4</sup>Department of Neurosurgery, Korle Bu Teaching Hospital, Accra, Ghana.

### **Authors' contributions**

*This work was carried out in collaboration between both authors. Author KAM as the primary author put together this work and did the entire write up of this manuscript. Author HA did a thorough review of the facts, presented and edited the work. Both authors read and approved the final manuscript.*

### **Article Information**

DOI: 10.9734/IJMPCR/2016/31587

#### Editor(s):

(1) Nurhan Cucer, Medical Biology Department, Faculty of Medicine, Erciyes University, Turkey.

#### Reviewers:

(1) Caroline Iyalla, University of Port Harcourt, Nigeria.

(2) Anonymous, University in Thunder Bay, Canada.

(3) Silvana Guerriero, University of Bari, Italy.

Complete Peer review History: <http://www.sciencedomain.org/review-history/18045>

**Case Study**

**Received 15<sup>th</sup> January 2017**  
**Accepted 24<sup>th</sup> February 2017**  
**Published 4<sup>th</sup> March 2017**

### **ABSTRACT**

Blastomycosis is a fungal infection that mostly involves the skin and lung with only a 5-10% incidence of Central nervous system involvement [1]. It occurs worldwide but it is endemic to areas like the Midwestern United States, Manitoba and Ontario provinces of Canada and equally affects both immunocompetent and immunocompromised individuals with the likelihood of being more aggressive in the latter [1]. We present a 51 year old hypertensive factory machine operator from a Blastomyces non- endemic area of Cape Town, South Africa with no immunosuppressive condition who presented with worsening protracted headaches and cerebellar signs. Brain Computed Tomography and Magnetic Resonance imaging appearances of a heterogeneously enhancing left cerebellar hemisphere lesion posed an initial diagnostic dilemma which led to worsening of the patient's clinical condition from hydrocephalus as a result of increased perilesional oedema and

\*Corresponding author: E-mail: [kamson547@gmail.com](mailto:kamson547@gmail.com);

compression of the fourth ventricle. Eventual biopsy and culture after craniectomy yielded a diagnosis of primary cerebellar blastomycosis which necessitated a 6 week intravenous treatment with amphotericin B followed by oral itraconazole for 12 months leading to complete radiological resolution of the cerebellar lesion and clinical resolution of the headaches and ataxia.

*Keywords: Blastomycosis; immunocompromised; immunocompetent; Blastomyces; Blastomyces dermatitidis.*

## ABBREVIATIONS

*HIV: Human Immunodeficiency Virus; MRI: Magnetic Resonance Imaging; MRA: Magnetic Resonance Angiography; CT Scan: Computed Tomography Scan.*

## 1. INTRODUCTION

Blastomycosis is a fungal infection that mostly involves the skin and lung only rarely involving the Central Nervous System (CNS) with an incidence of 5-10% [1]. Central nervous system Blastomycosis without evidence of lung or other organ involvement is very rare [1]. Leers et al. [2] reported cerebellar Blastomycosis in 1972 as a primary infection with no meningitis as was the situation with our index case. The most common primary CNS manifestation is basilar leptomeningitis followed by solitary or multiple brain parenchymal masses then epidural abscesses. It occurs worldwide but is endemic to the Midwestern United States, Manitoba and Ontario provinces of Canada [1]. The optimal habitat for *Blastomyces* is wetland enriched with animal droppings and decaying vegetation. The most common route of infection is by inhalation of conidia released from disruption of soil containing the fungus. It can also be acquired by direct skin inoculation [1]. Transmission from dog bite has also been reported in literature [3].

We describe the clinical course and management of an immunocompetent patient treated for cerebellar blastomycosis in the Department of Neurosurgery of a Teaching Hospital in Cape Town, South Africa.

## 2. CASE PRESENTATION AND MANAGEMENT

A 51 year old male, known hypertensive, HIV negative and a non-diabetic factory machine operator presented to a teaching hospital in Cape Town, South Africa with a 7 month history of gradually worsening headaches. The headaches were aggravated by almost any form of straining including coughing and passing stools. They became more localized to the

occipital area and more difficult to control with common analgesics over time. He also had a 2 months history of worsening ataxia and a 3 weeks history of intermittent vomiting, especially after meals. He had no fever and no chest symptoms. A Computed Tomography (CT) scan of the head done at this stage showed a heterogeneously enhancing left cerebellar mass lesion with some compression of the fourth ventricle, attenuation of the basal cisterns and mild enlargement of the third ventricle and both lateral ventricles. Differential diagnoses of metastasis, infective lesion and a resolving hematoma were made. He was thus investigated for a possible primary neoplasm which included chest x-rays and abdomino-pelvic ultrasonography. The serum levels of various tumour markers like alpha fetoprotein, prostatic specific antigen and carcinoembryonic antigen were also measured. None of the tumour markers were raised and no primary neoplastic lesion was found. Brain Magnetic Resonance Imaging (MRI) done at this stage showed a left cerebellar lesion which demonstrated heterogeneity on T2 (Fig. 2) and a heterogeneous post gadolinium enhancement showing several cystic areas with thick enhancing walls (Figs. 3 and 4). The patient however remarkably improved clinically on steroids and analgesics.

In consultation with the Neuro-radiologist, a diagnosis of a resolving cerebellar bleed was made and the patient discharged to be followed up with an MRI in one month time including a gradient echo with or without Magnetic Resonance Angiography (MRA).

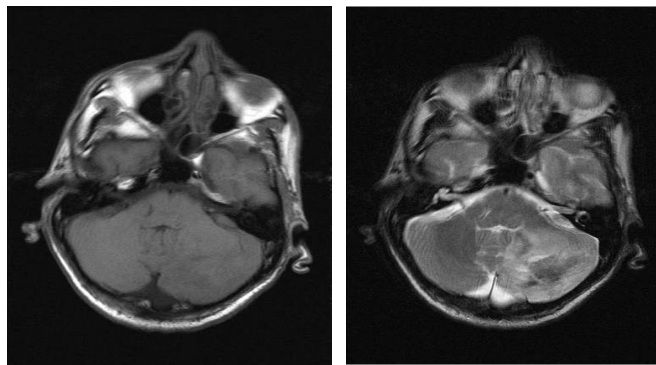
The patient however presented 3 days after discharge with a sudden onset of a very severe intractable headache with vomiting and confusion. An urgent Brain CT scan done revealed the same left cerebellar heterogeneous

lesion but now with some surrounding vasogenic edema, marked compression of the fourth ventricle and severe acute hydrocephalus (Figs. 5 and 6).

A ventriculoperitoneal shunt was immediately placed (Fig. 7), following which the patient improved clinically. A left occipital craniectomy was then done and an open biopsy of the cerebellar lesion was performed and sent for histopathology as well as microbiological analysis. The histopathology report came as fragments of gliotic brain tissue with multinucleated giant cells and broad based budding yeasts with double contour refractile walls and areas of pseudo hyphae formation. Ziehl-Neelsen (ZN) staining was negative. Microbiology cultures yielded a fungus which was subsequently confirmed to be a *Blastomyces dermatitidis*. Treatment with intravenous amphotericin B was then commenced at this

stage and continued for 6 weeks. In addition, replacement of magnesium, potassium, calcium and iron were intermittently done to correct the concurrent derangements in the serum electrolyte levels over the treatment period.

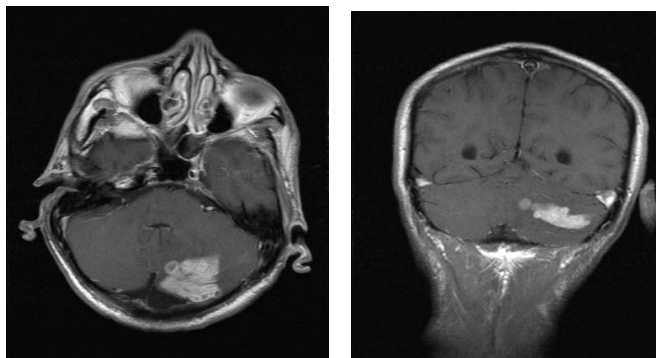
The 6 weeks course of intravenous Amphotericin B was then followed with a 6 months course of oral Itraconazole. Itraconazole was used instead of the recommended Voriconazole because of unavailability (Voriconazole was out of stock at the pharmacy). The patient was then monitored clinically with weekly follow up visits for one month, 2 weekly visits for 2 months then monthly visits for the last 3 months of treatment. Serial brain CT scans done during these follow up visits showed progressive decrease in the size of the lesion with corresponding improvements in the patient's clinical condition over the treatment period (depicted in Figs. 10 and 11 of this text).



(1)

(2)

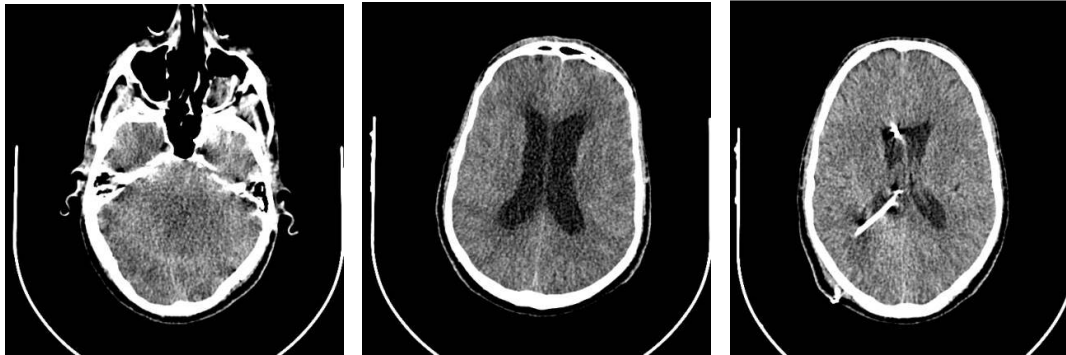**Figs. 1 and 2. Axial T1 (1) and Axial T2 (2) Brain MRI scans of our index patient showing a heterogeneous left cerebellar hemispheric lesion on T2**



(3)

(4)

**Figs. 3 and 4. Axial T1 post gadolinium contrast (3) and Coronal T1 post gadolinium contrast (4) Brain MRI scans of the patient showing a heterogeneous contrast enhancing lesion with areas of thick ring enhancement in the left cerebellar hemisphere**

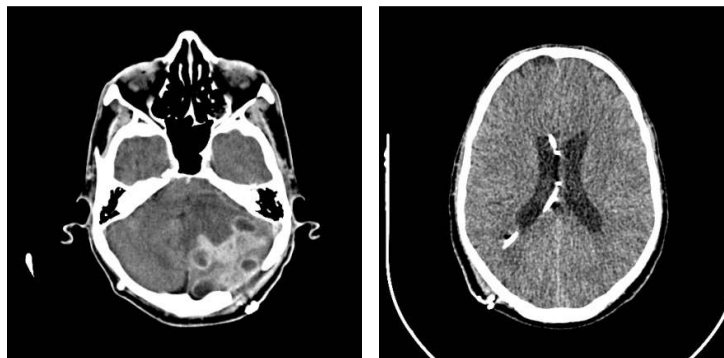


(5)

(6)

(7)

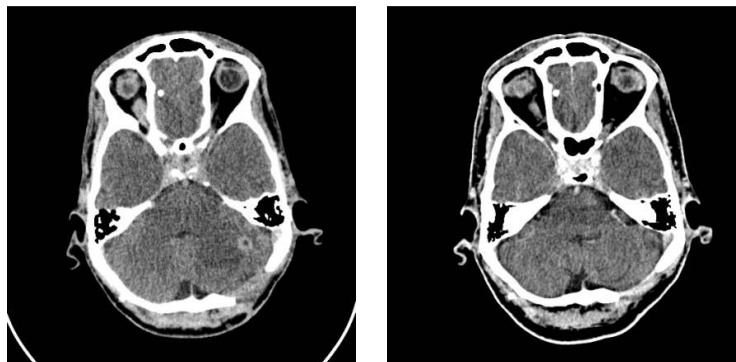
**Figs. 5-7. Non-contrast Brain CT scans just before (5 and 6) and after a ventriculoperitoneal shunt placement (7)**



(8)

(9)

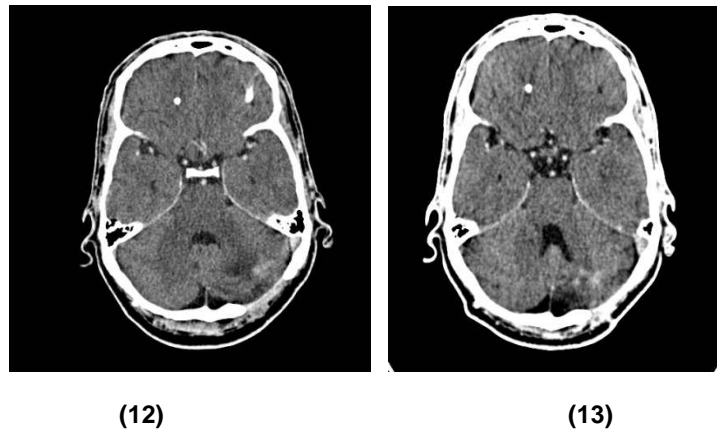
**Figs. 8 and 9. Post contrast CT Brain scan after 6 weeks of treatment with intravenous Amphotericin B showing the area of the sub-occipital craniectomy with the residual heterogeneous ring enhancing left cerebellar hemispheric lesion after open biopsy (8) and the VP shunt *in situ* (9)**



(10)

(11)

**Figs. 10 and 11. Post contrast CT Brain scans after 3months (10) and 5 months (11) of oral Itraconazole treatment**



**Figs. 12 and 13. Post contrast Brain CT scan after 6 months of oral Itraconazole (12) and 6 months after completion of treatment with complete resolution of the left cerebellar hemispheric lesion and an open fourth ventricle (13)**

A Brain CT scan at the end of the treatment period showed complete resolution of the left cerebellar hemisphere lesion with an open fourth ventricle and patent basal cisterns with complete resolution of the patient's symptoms including the ataxia and the headaches (as shown in above Figs. 12 and 13 of this text). The patient has since returned to his formal work as a factory machine operator without any residual neurological deficit.

### 3. DISCUSSION

Clinical presentation of CNS Blastomycosis may vary from subclinical infection to a rapidly progressive dissemination and death. Symptoms may include weight loss, malaise and fatigue as well as features referable to the CNS [1]. Bariola et al reported in his multicenter review of 22 patients that headache was the most common symptom (86%) [4]. The likelihood of infection is equal amongst immunocompetent and immunosuppressed individuals but may be more aggressive in the latter [1]. Cerebrospinal fluid (CSF) examination findings typically include pleocytosis with neutrophilic or lymphocytic predominance and elevated protein but staining and fungal culture from CSF is mostly negative and cross reactions with other fungal agents like *Histoplasma* may give a diagnostic dilemma with the use of *Blastomyces* antigen detection tests [1,4]. Biopsy or resection may thus provide a better diagnostic yield and such cultures yield growth with microscopic features of necrotizing granulomatous inflammation with yeast forming fungi [1,5]. Histopathologic findings include

polymorphonuclear leukocytes clustered granulomas usually non-caseating, budding yeast cells with capsules, positive staining with Grocott-methenamine silver (GMS) and weakly positive Acid Fast stain [1,5]. The biopsy specimen culture yields the pathogen in 71% of histology confirmed cases having studied 16 cases with proven or probable CNS Blastomycosis [6]. The imaging characteristics of CNS Blastomycosis are difficult to differentiate from CNS infections from other fungal entities especially *Histoplasma capsulatum* and *Coccidioides immitis* [1] MRI consistently demonstrates an abnormality in all cases compared to 58% of CT scans [6]. Magnetic Resonance Spectroscopy (MRS) may show diminished N-acetyl aspartate (NAA) to creatine ratio (1.10), normal choline to NAA ratio (0.82), normal choline to creatine ratio (0.9) and a diminished myoinositol to creatine ratio (0.39). There may be peaks between 3.6 and 3.8 ppm over the enhancing area thought to represent a trehalose peak [7]. Amphotericin B is the initial treatment of choice for especially immunocompromised patients, those with life threatening or CNS disease and those for whom azole treatment has failed. Amphotericin B is also approved for treating Blastomycosis in pregnant women [8]. The combination of surgical resection with antifungal therapy is considered to be the optimal management of solitary fungal brain abscesses [1,5]. The disturbing side effects of amphotericin B including hepatic and renal insufficiencies and electrolyte imbalances should however be well noted for prompt action.

The same diagnostic dilemma was encountered in our management of this patient as repeatedly reported in literature. Our index patient is an immunocompetent patient from a non-endemic area without any travel history who initially presented with headaches and clinical features referable to the cerebellum without any other organ or system involvement. The 63 year old patient reported by Munich SA et al had a history of non-Hodgkin's lymphoma 9 years prior and was in sustained remission after treatment with chemotherapy and radiation [9]. Routine chest Xray also showed a non-specific left upper lobe opacities and CT findings were consistent with pneumonia [9]. Our patient's scenario on the background of a history of hypertension lowered the clinicians' suspicion index toward an infective cause and less so a fungal cause. The non-usage of other MRI modalities like Diffusion Weighted Imaging (DWI) and Magnetic Resonance Spectroscopy (MRS) in this case to further examine the cerebellar lesion might have reduced the chance of being able to make an earlier definitive diagnosis and hence a prompt institution of the correct treatment. Again, an early biopsy followed by histopathological and microbiological tests would have resolved the initial diagnostic dilemma irrespective of the patient's non-specific history and clinical features. Had an early correct diagnosis been made in our index case the complication of hydrocephalus might have been prevented. A high index of suspicion for atypical brain infections like fungal brain infections is still to be maintained by clinicians irrespective of patient's travel history, location or immune status. And therefore a more exhaustive use of all available investigative tools should be employed to be able to make an early diagnosis and expedite early appropriate treatment in order to improve patient outcomes and prevent complications.

#### 4. CONCLUSION

CNS Blastomycosis like other fungal brain infections usually present non-specifically and particularly do not always necessarily only occur in immunocompromised individuals or individuals from endemic areas. Imaging findings may be non-specific making early biopsy/excision and histo-microbiological confirmation very important in making an early diagnosis. Surgical resection followed by long term treatment with antifungal agents remains the mainstay of treatment of patients with fungal intracranial space occupying lesions.

#### CONSENT

Consent taken from patient but patient's anonymity still maintained.

#### ETHICAL APPROVAL

Ethics approval was given by the University of Stellenbosch, Cape Town, South Africa Research Ethics board for this study.

#### COMPETING INTERESTS

Authors have declared that no competing interests exist.

#### REFERENCES

1. Stavrakis C, Narayan A, Voronel O. Cerebral blastomycosis: Radiologic-Pathologic correlation of solitary CNS blastomycosis mass-like infection. *J Clin Imaging Sci*. 2015;29:5:30. DOI: 10.4103/2156-7514.157854 [PubMed]
2. Leers WD, Russell NA, Laroye G. Cerebellar abscess due to Blastomyces dermatitidis. *Can Med Assoc J*. 1972; 107(7):657-60. [PubMed]
3. Gnann JW Jr, Bressler GS, Bodet CA 3rd, Avent CK. Human blastomycosis after a dog bite. *Ann Intern Med*. 1983;98:48-9. [PubMed]
4. Bariola JR, Perry P, Pappas PG, Proia L, Shealey W, Wright PW, et al. Blastomycosis of the central nervous system: A multicenter review of diagnosis and treatment in the modern era. *Clin Infect Dis*. 2010;50:797-804.
5. Saccente M, Woods GL, Clinical and laboratory update on blastomycosis. *Clin Microbiol Rev*. 2010;23:367-81. [PubMed]
6. Bush JW, Wuerz T, Embil JM, Del Bigio MR, McDonald PJ, Krawitz S. Outcomes of persons with blastomycosis involving the central nervous system. *Diagn Microbiol Infect Dis*. 2013;76(2):175-81. DOI: 10.1016/j.diagmicrobio.2013.03.002
7. Vachhani JA, Lee WC, Desanto JR, Tsung AJ. Magnetic resonance spectroscopy imaging characteristics of cerebral blastomycosis. *Surg Neurol Int*. 2014;5:80. DOI: 10.4103/2152-7806.133306 [PubMed]

8. Chapman SW, Dismukes WE, Proia LA, Bradsher RW, Pappas PG, Threlked MG, et al. Clinical practice guidelines for the management of blastomycosis: 2008 update by the Infectious Disease Society of America Clin Infect Dis. 2008;46:1801–12.
9. Munich SA, Johnson AK, Ahuja SK, Venizelos A, Byrne RW. Large cerebellar mass lesion: A rare intracranial manifestation of blastomycosis. Surg Neurol Int. 2013;4:141. DOI: 10.4103/2152-7806.119882 [PubMed]

---

© 2016 Agyen-Mensah and Akoto; This is an Open Access article distributed under the terms of the Creative Commons Attribution License (<http://creativecommons.org/licenses/by/4.0>), which permits unrestricted use, distribution, and reproduction in any medium, provided the original work is properly cited.

*Peer-review history:*  
*The peer review history for this paper can be accessed here:*  
<http://sciencedomain.org/review-history/18045>