



Incidental Detection of a Right atrial wire Attached Mobile Thrombus of an Implantable Cardioverter Defibrillator (ICD) in a Case of MALT Lymphoma

Norah F. Aleid ^{a,b}, Afnan M. Alsaad ^{a,b},
Abdullah A. Alkhateeb ^{a,b}, Mohamed A. Soliman ^{a,b},
Yazan H. Mustafa ^{a,b}, Ayman F. Soliman ^{a,b,c*}
and Muneera Altaweel ^{a,b}

^a King Abdulaziz Hospital, MNGHA, Al Ahsa, Saudi Arabia.

^b King Abdullah International Medical Research Center (KAIMRC), Al Ahsa, Saudi Arabia.

^c King Saud bin Abdulaziz University for Health Sciences, COAMS-A, Al Ahsa, Saudi Arabia.

Authors' contributions

This work was carried out in collaboration among all authors. All authors read and approved the final manuscript.

Article Information

DOI: 10.9734/CA/2023/v12i4358

Open Peer Review History:

This journal follows the Advanced Open Peer Review policy. Identity of the Reviewers, Editor(s) and additional Reviewers, peer review comments, different versions of the manuscript, comments of the editors, etc are available here: <https://www.sdiarticle5.com/review-history/105112>

Case Report

Received: 08/06/2023

Accepted: 11/08/2023

Published: 16/08/2023

ABSTRACT

Implantable cardioverter defibrillators (ICD) are widely used in primary prevention for cardiomyopathy patients.

A 57-year-old male with dilated cardiomyopathy post ICD implantation was found to have an incidental asymptomatic echocardiogram finding of a mobile thrombus attached to the tip of the ICD wire in the right atrium. The thrombosis is probably due to a hypercoagulability state in patient with Cardiomyopathy and MALT lymphoma. The purpose of this case report is to highlight accidental discoveries of ICD wire thrombi and the appropriate therapeutic strategy.

*Corresponding author: E-mail: Solimana@NGHA.med.sa, Solimana@ksau-hs.edu.sa, SolimanA@mngha.med.sa;

Keywords: *Thrombus; echocardiography; Implantable Cardioverter Defibrillator (ICD).*

1. INTRODUCTION

Implantable cardioverter-defibrillators (ICDs) became increasingly popular among patients with high comorbidity levels including heart failure, myocardial infarction, and other underlying morbidities frequently found among ICD recipients [1]. ICDs are associated with an elevated risk of complications, including venous thromboembolism (VTE) [2,3]. Furthermore, wire-related venous thrombosis is a recognized complication of cardiac implantable electronic devices (CIEDs) [4].

Clot formation on device wires is poorly understood. Most of these thrombi are asymptomatic and typically discovered as incidental echocardiographic findings. However, symptomatic complications are much less common, seen in only 0-6% of patients [5-6]. Similarly, symptomatic pulmonary embolism after pacemaker/ICD implantation is relatively rare, seen in 0-5% of patients [5,7,8]. However, the incidence of asymptomatic pulmonary embolism is much more common.

Cancer-associated thrombosis is one of the main causes of morbidity and mortality in cancer patients [9]. MALT lymphoma is a slow growing lymphoma. The stomach is where they are most frequently diagnosed (gastric MALT). However, they can also appear in other organs including the thyroid and lung.

Several imaging tools have been used to assess thrombosis in the great veins of the upper or lower extremities and their tendency to transmit as emboli to the lungs. It hasn't been evaluated whether thrombi are present in the intracardiac section of the wires, however, on transthoracic echocardiography (TTE), intracardiac thrombi can occasionally be visible, but because of the inadequate resolution of TTE, their existence can be easily missed [4].

Herein, we present a case of a large right atrial thrombus found incidentally attached to an ICD wire diagnosed by transthoracic echocardiography in patient with Malta lymphoma.

2. CASE REPORT

A 57-year-old male had an ICD implanted on 16/1/2010 (ICD is Biotronik & not MRI

compatible) as part of the treatment for dilated cardiomyopathy. He has a history of MALT lymphoma which he received chemotherapy for. The dilated cardiomyopathy was most likely chemotherapy induced.

The patient was directly admitted to the critical care unit under cardiology for an incidental finding on his echocardiogram of a mobile mass attached to the tip of the wire of his ICD in the right atrium. The mass measured 3.1 x 0.8 cm (Fig. 2). Patient was asymptomatic, had no history of leg pain or swelling, and no history of long distance travel or immobility. He had visited the emergency department a few days ago with a complaint of shortness of breath and chest pain. His ECG showed sinus rhythm, occasional PVCs and wide spread inverted T wave. (Fig. 1) He was offered admission, but the patient signed against medical advice after symptomatic relief upon receiving intravenous diuretics. The patient had an echocardiogram as an outpatient where the incidental finding has been discovered.

The patient was conscious, alert, and oriented upon physical examination, and not in distress. He was vitally stable and afebrile during his admission. His chest, cardiovascular, abdomen & lower limb examination were unremarkable. Electrocardiogram of the patient was normal. Further findings on his echocardiography showed left ventricular systolic function was moderately impaired with moderate mitral regurgitation and mild tricuspid regurgitation present with a right ventricular systolic pressure (RVSP) of 45 mmHg. His complete blood count, electrolytes, and cardiac enzymes were all within normal range. A bilateral Lower limb Doppler was carried out to rule out the possibility of deep venous thrombosis (DVT) and the results were negative.

The patient was started on Warfarin with bridging therapeutic Enoxaparin with the aim of the International Normalised Ratio (INR) between 2 and 3. Echocardiogram was followed daily to assess the size of the thrombotic mass, and medical opinion was obtained from the infectious disease team regarding starting empirical antibiotics. Antibiotics were not recommended as the patient was afebrile and clinically stable with negative initial blood culture. The hematology-oncology team was consulted regarding the previous history of MALT lymphoma and the probability of recurrence, which may trigger the formation of a thrombus. As the figures show

(Figs. 3, 4, 5), the thrombus's size decreased in the consequent echocardiogram. Furthermore, after four weeks of Warfarin, a mobile thrombus was not be detected on the echocardiogram (Fig 6). The follow-up echocardiogram did not show a recurrence of the thrombus (Fig. 7).

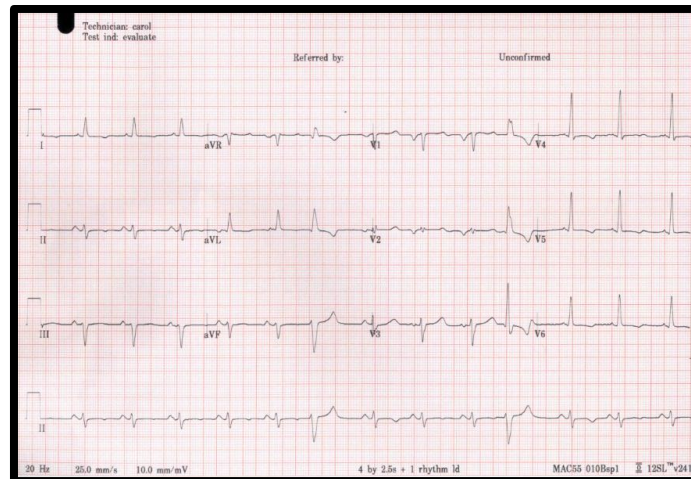
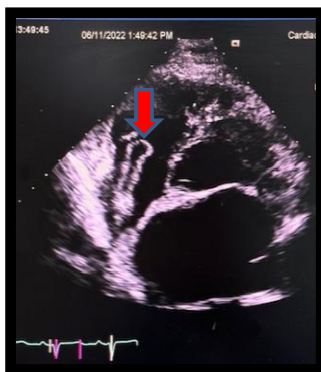
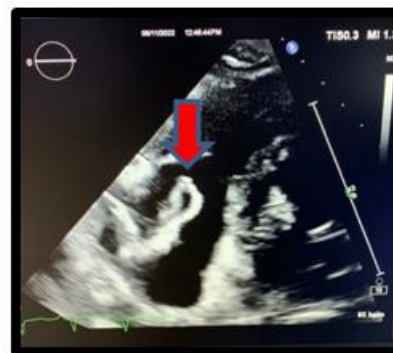

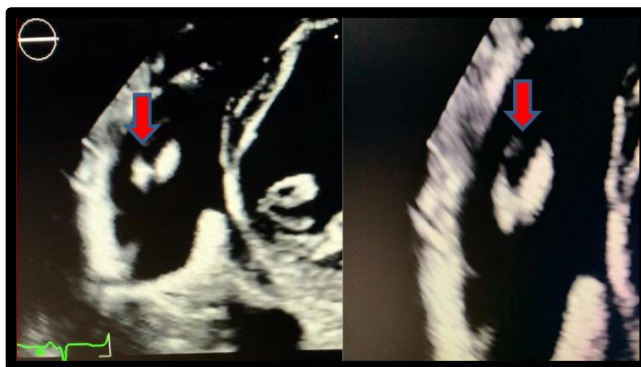Fig. 1. ECG



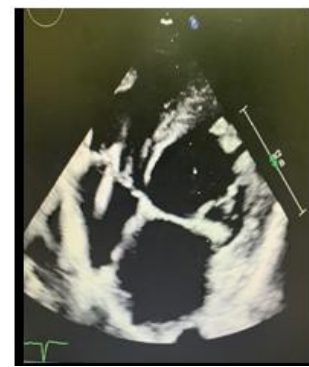**Fig. 2. Echocardiogram on 6/11/2022
(The arrow points to the thrombus)**



**Fig. 3. Echocardiogram on 8/11/2022
(The arrow points to the thrombus)**



**Fig. 4. Echocardiogram on 10/11/2022
(The arrow points to the thrombus)**



**Fig. 5. Echocardiogram on 12/11/2022
(Thrombus was no longer seen)**

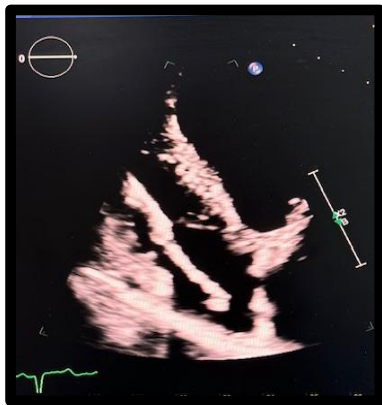

Fig. 6. Echocardiogram on 15/12/2022 (Thrombus was no longer seen)

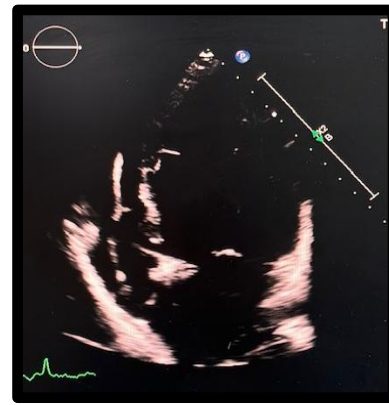


Fig. 7. Echocardiogram on 12/2/2023 (Thrombus was no longer seen)

3. DISCUSSION

In this report, we presented a case of an incidentally discovered thrombus on the ICD wire in an asymptomatic male patient. Around 30-45% of patients on permanent pacemakers experience pacemaker wire-induced venous thrombosis following implantation. Only 0.6-3.5% of individuals developed severe thromboembolic consequences [10]. Although the pathogenesis of pacemaker/ICD wire thrombosis is not entirely understood, it is known that this condition typically evolves in certain conditions that increase thrombus buildup and formation [11].

Heart failure and conditions with hypercoagulable state such as underlying malignancies, anti-thrombin III, protein S and protein C deficiencies can predispose to thrombus formations. It has been demonstrated that the thrombogenicity of pacemaker's wires to various kinds of insulation varies. For example, polyurethane wires may have lesser thrombogenicity than silicone wires [12]. It is also crucial to note that atrial fibrillation increases the risk of developing thrombus formation in cardiac devices by eight folds [10]. In our case, the patient did not have atrial fibrillation nor was he in heart failure. Considering the previous history of treated lymphoma, the patient showed no signs or symptoms of active malignancy.

Patients with pacemaker/ICD wire thrombosis may exhibit vague symptoms, which might delay diagnosis. The majority of right atrial pacemaker thrombosis are discovered incidentally on echocardiogram [13]. Patients may present with atypical arrhythmias, right-sided heart failure symptoms, or acute pulmonary embolism [14]. Therefore, paying attention to such presentations

in patients with cardiac devices is essential. In our case, the patient was free of symptoms with no features of atrial fibrillation, heart failure, or pulmonary embolism. Even though our patient was not thoroughly investigated for any other hypercoagulable conditions, we suspected malignancy activation as the most probable scenario, given the history of previously treated lymphoma. Furthermore, despite the significant association between cancer and thrombosis, the ECPC study is the largest of its type among CAT patients and careers. It identified significant gaps in patient awareness and knowledge of CAT as well as a need for educational CAT-related discussions and interventions [9].

There's another scenario we're thinking about in this patient. This thrombus may be a thrombus in transit from deep vein thrombosis, and it's been detected by the ICD wire. We don't have proof of that scenario, however.

There are no specific guidelines for treating pacemaker/ICD wire thrombus. According to some researchers, the choice of treatment should be made based on the size of the thrombus and the patient's clinical presentation. These different modalities include anticoagulation, thrombolysis, or surgical option [15]. However, in the patient we present we start him on Warfarin with Enoxaparin bridging to reach an INR of 2 to 3. The thrombus size decreased in the consequent imaging until it resolved completely. Our case is unique given the negative available risk factors causing the formation of ICD wire thrombus. This case demonstrates the effectiveness of Warfarin as an anticoagulant therapy for the complete clearance of thrombus developed on the pacemaker/ ICD wires.

4. CONCLUSION

In patients with an ICD, an asymptomatic thrombus can be found incidentally on cardiac echocardiography. Therefore, following up on these patients with echocardiograms, especially those with high-risk factors like cancer patients are important.

This case demonstrates the effectiveness of Warfarin as an anticoagulant therapy for the complete clearance of a thrombus developing on ICDs.

This patient group should be considered for anticoagulation to prevent further complications, but no data for the duration of the anticoagulation has been defined. Furthermore, no available score can determine which patient has to be on long-term or life-term anticoagulation therapy.

CONSENT

As per international standard or university standard, patient(s) written consent has been collected and preserved by the author(s).

ETHICAL APPROVAL

Institutional Review Board (IRB) approval was obtained, and the study follows the Good Clinical Practice (GCP) guideline.

COMPETING INTERESTS

Authors have declared that no competing interests exist.

REFERENCES

- Schmidt M, Pedersen SB, Farkas DK, Hjortshøj SP, Bøtker HE, Nielsen JC, et al. Thirteen-year nationwide trends in the use of implantable cardioverter-defibrillators and subsequent long-term survival. *Heart Rhythm*. 2015;12:2018–27
- Sørensen HT, Horvath-Puho E, Lash TL, Christiansen CF, Pesavento R, Pedersen L, et al. heart disease may be a risk factor for pulmonary embolism without peripheral deep venous thrombosis. *Circulation*. 2011;124:1435–41.
- Riva N, Donadini MP, Ageno W. Epidemiology and pathophysiology of venous thromboembolism: Similarities with atherothrombosis and the role of inflammation. *Thromb Haemost*. 2015; 113:1176–83.
- Supple GE, Ren JF, Zado ES, Marchlinski FE. Mobile thrombus on device wires in patients undergoing ablation: Identification, incidence, location, and association with increased pulmonary artery systolic pressure. *Circulation*. 2011;124:772–8.
- Da Costa SS, Scalabrini Neto A, Costa R, Caldas JG, Martinelli Filho M. Incidence and risk factors of upper extremity deep vein lesions after permanent transvenous pacemaker implant: a 6-month follow-up prospective study. *Pacing Clin Electrophysiol*. 2002;25:1301–1306.
- Oginosawa Y, Abe H, Nakashima Y. The incidence and risk factors for venous obstruction after implantation of transvenous pacing wires. *Pacing Clin Electrophysiol*. 2002;25:1605–1611.
- Seeger W, Scherer K. Asymptomatic pulmonary embolism following pacemaker implantation. *Pacing Clin Electrophysiol*. 1986;9:196–199.
- Korkeila PJ, Saraste MK, Nyman KM, Koistinen J, Lund J, Juhani Airaksinen KE. Transesophageal echocardiography in the diagnosis of thrombosis associated with permanent transvenous pacemaker electrodes. *Pacing Clin Electrophysiol*. 2006;29:1245–1250.
- How well do European patients understand cancer-associated thrombosis? A patient survey. Anna Falanga a, Charis Girvalaki b, Manuel Monreal c, Jacob C Easaw d, Annie Young e *Cancer Treatment and Research Communications*. Volume 31, 2022, 100557 <https://doi.org/10.1016/j.ctarc.2022.100557>
- Barakat K, et al. Transvenous pacing wire-induced thrombosis: A series of cases with a review of the literature. *Cardiology*. 2000;93(3):142-8. DOI:10.1159/000007018
- Rahbar AS, Azadani PN, Thatipelli S, Fleischmann KE, Nguyen N, Lee BK. Risk factors and prognosis for clot formation on cardiac device wires. *Pacing Clin Electrophysiol*. 2013;36:1294–1300.
- Palatianos GM, Dewanjee MK, Panoutsopoulos G, Kapadvanjwala M, Novak S, Sfakianakis GN. Comparative thrombogenicity of pacemaker wires. *Pacing Clin Electrophysiology*. 1994; 17(2):141-145. DOI:10.1111/j.1540-8159.1994.tb01364.x

13. Fabijanić D, Giunio L, Vujčić M, Vuković I, Ermacora R, Knezević N. Right atrial pacemaker wire thrombosis incidentally detected by transesophageal echocardiography. *Coll Antropol.* 2005; 29(1):159-161.
14. Wierzbowska K, Krzeminska-pakula M, Marszal-marciniak J, Drozd J, Zaslonka J, Kasprzak J.D. Symptomatic atrial pacemaker wire thrombosis: detection by echocardiography and successful surgical treatment. *Pacing Clin Electrophysiology.* 2001;24:391-393. Available:doi.org/10.1046/j.1460-9592.2001.00391.x
15. Coleman DB, DeBarr DM, Morales DL, et al. Pacemaker wire thrombosis treated with atrial thrombectomy and biventricular pacemaker and defibrillator insertion. *Ann Thorac Surg.* 2004;78:e83–84.

© 2023 Aleid et al.; This is an Open Access article distributed under the terms of the Creative Commons Attribution License (<http://creativecommons.org/licenses/by/4.0>), which permits unrestricted use, distribution, and reproduction in any medium, provided the original work is properly cited.

Peer-review history:

The peer review history for this paper can be accessed here:
<https://www.sdiarticle5.com/review-history/105112>