



# MPO-ANCA Associated Vasculitis Following COVID-19 Vaccination – A Case Report

COLLECTION: GME  
RESEARCH DAY 2021

**PUBLISHED ABSTRACT**

**MAHMOUD KHALIFA** 

**YARA ADEL ALTAHAN** 

**PAAVANA VARANASI** 

*\*Author affiliations can be found in the back matter of this article*



Levy  
Library  
Press

## ABSTRACT

Whether autoimmune or rheumatic disease can be precipitated after vaccination is controversial. Only epidemiological studies or clinical trials with an extremely large sample size can allow for a consistent assessment of the relative risk of vaccine-related incidence. Studies with such large sample sizes are complex, difficult to perform, and costly, which limit their administration. There exists no minimum criteria for diagnosing vaccine-related autoimmune diseases, this question must be analyzed on a case-by-case basis.

Although our report does not prove a causal association between vaccination and vasculitis, it seems possible that in rare cases, vaccination might induce vasculitic disease. While the possibility of autoimmune disease is very real, without vaccinations the SARS-CoV-2 pandemic will spread unchecked, bringing with it a slew of multi-system disorders, including autoimmune diseases both in the present and future (**Table 1, Figures 1, 2**).

CORRESPONDING AUTHOR:

**Mahmoud Khalifa**

BronxCare Health System, US  
[msakms1991@gmail.com](mailto:msakms1991@gmail.com)

---

KEYWORDS:

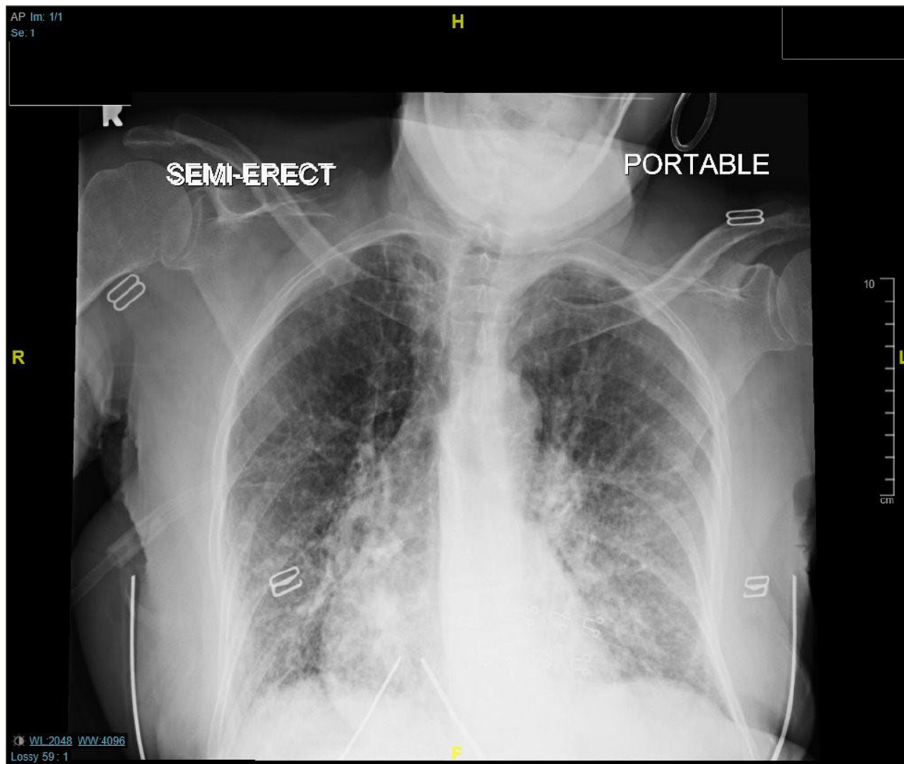
COVID-19 vaccination;  
MPO-ANCA; Vasculitis;  
Autoimmune; SARS-CoV-2;  
COVID-19

TO CITE THIS ARTICLE:

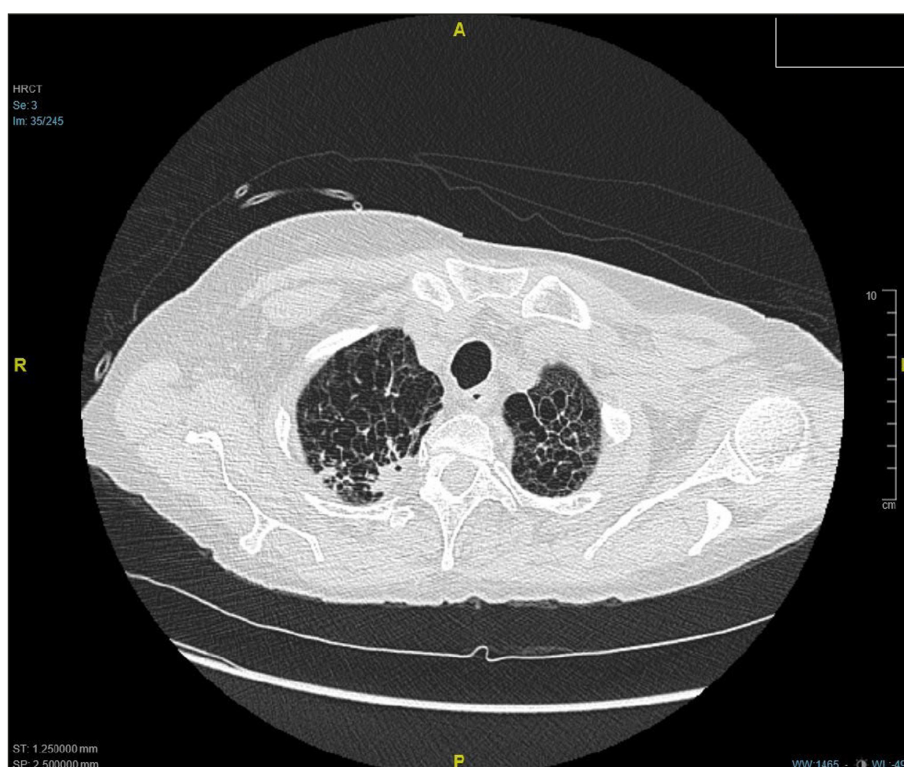
Khalifa M, Altahan YA, Varanasi P. MPO-ANCA Associated Vasculitis Following COVID-19 Vaccination – A Case Report. *Journal of Scientific Innovation in Medicine*. 2021; 4(2): 5, pp. 1–3. DOI: <https://doi.org/10.29024/jsim.101>

ACUTE-KIDNEY INJURY WORK UP REQUESTED	RESULT
C3	135.0 [90.0–150.0 mg/dL]
C4	20.0 [16.0–47.0 mg/dL]
Anti-nuclear antibody (ANA) screen	Negative
Anti-Glomerular basement membrane antibody	Undetectable
Anti-DNA antibody	Undetectable
ANCA-MPO antibody	535.4 AI
ANCA-Proteinase-3 antibody	Undetectable

**Table 1** Results of the workup for renal failure.



**Figure 1** CXR showing diffuse bilateral interstitial/alveolar airspace infiltrates.





**Figure 2** HRCT chest showing spiculated densities in the bilateral lung apices.


## COMPETING INTERESTS

The authors have no competing interests to declare.

## AUTHOR AFFILIATIONS

**Mahmoud Khalifa**  [orcid.org/0000-0002-7603-507X](https://orcid.org/0000-0002-7603-507X)  
BronxCare Health System, US

**Yara Adel Altahan**  [orcid.org/0000-0003-0435-0895](https://orcid.org/0000-0003-0435-0895)  
Royal College of Surgeons in Ireland, RCSI, IE

**Paavana Varanasi**  [orcid.org/0000-0001-9669-397X](https://orcid.org/0000-0001-9669-397X)  
BronxCare Health System, US

TO CITE THIS ARTICLE:  
Khalifa M, Altahan YA, Varanasi  
P. MPO-ANCA Associated  
Vasculitis Following COVID-19  
Vaccination – A Case Report.  
*Journal of Scientific Innovation  
in Medicine*. 2021; 4(2): 5,  
pp. 1–3. DOI: [https://doi.  
org/10.29024/jsim.101](https://doi.org/10.29024/jsim.101)

Submitted: 04 May 2021  
Accepted: 04 May 2021  
Published: 24 May 2021

COPYRIGHT:  
© 2021 The Author(s). This is an  
open-access article distributed  
under the terms of the Creative  
Commons Attribution 4.0  
International License (CC-BY  
4.0), which permits unrestricted  
use, distribution, and  
reproduction in any medium,  
provided the original author  
and source are credited. See  
[http://creativecommons.org/  
licenses/by/4.0/](http://creativecommons.org/licenses/by/4.0/).

*Journal of Scientific Innovation  
in Medicine* is a peer-reviewed  
open access journal published  
by Levy Library Press.