



Diagnosis of Genital Tuberculosis by Cartridge Based Nucleic Acid Amplification Test in Subfertile Women of Rural Hospital

**Asawari Deo^{a*#}, Deepti Shrivastava^{a≡}, Harsha Shekhawat^{a#}
and Uttara Shelke^{a#}**

^a *Department of Obstetrics and Gynaecology, Jawaharlal Nehru Medical College, Sawangi [M], Wardha, India.*

Authors' contributions

This work was carried out in collaboration among all authors. All authors read and approved the final manuscript.

Article Information

DOI: 10.9734/JPRI/2021/v33i63A35230

Open Peer Review History:

This journal follows the Advanced Open Peer Review policy. Identity of the Reviewers, Editor(s) and additional Reviewers, peer review comments, different versions of the manuscript, comments of the editors, etc are available here: <https://www.sdiarticle5.com/review-history/81649>

Study Protocol

**Received 24 October 2021
Accepted 28 December 2021
Published 29 December 2021**

ABSTRACT

Tuberculosis has serious extra-pulmonary manifestations that are sometimes difficult to diagnose and thus left untreated. One such manifestation is female - genital tuberculosis (FGTB). Any diagnostic test is not efficient enough to prove the evidence of female genital tuberculosis. High level of clinical examination, detailed history of the patient, systemic examination, a series of tests to document M. tuberculosis as well as imaging techniques for characteristic structural changes are essential for the diagnosis.

There exists lot of diagnostic dilemmas for genital tuberculosis in the available literature. no single test is found confirmatory except for wet culture and histopathological positivity, which may become paucibacillary extrapulmonary sites and time consuming, which creates a need for an investigation which can provide quicker and accurate results. cartridge based nucleic acid amplification test [CBNAAT] being a molecular test may be rapid and promising to diagnose these lesions.

The diagnostic value of CBNAAT in detection of female genital tuberculosis seems to be limited, although it has a high positive predictive value.

[#] Junior Resident;

[≡] Professor;

*Corresponding author: E-mail: deoasawari94@gmail.com;

Keywords: CBNAAT, genital tuberculosis, FGTB.

1. INTRODUCTION

Tuberculosis may affect pulmonary as well as extra pulmonary locations (EPTB); former providing the bulk of burden. Extrapulmonary tuberculosis (EPTB) has many forms out of which common form being genitourinary Tb, with worldwide incidence of 27% with genital TB alone accounting for 9 % of all EPTB cases [1].

A survey by the Indian council for medical research, shows evidence which states that prevalence of female genital tuberculosis in India has been raised from 19 % in 2011 to 30% in 2015. For diagnosis and management of FGTB, a multicentric ICMR research team is working on making a nation-wide applicable algorithm [2,3].

Tb has serious extra-pulmonary manifestations that are sometimes difficult to diagnose and thus left untreated. One such manifestation is female - genital tuberculosis (FGTB), which was first identified by MORGAGNI in 1744 while performing an autopsy on a female who later died, of Tuberculous peritonitis [4–6].

There exists much of diagnostic issue with genital tuberculosis in the existing literature. No single test is proven confirmatory with the exception of wet culture and histological positivity, which may have become paucibacillary extrapulmonary sites and it is time intensive too. Cartridge based nucleic acid amplification test [CBNAAT] being a molecular test may be swift and promising to discover these lesions sooner and offer accurate diagnosis since, most of the diagnosis of female genital TB is made on significant level of clinical suspicion followed by a battery of diagnostic test most of which have limited utility. Performing hysterolaparoscopy has proven to be a useful tool for direct visualization of signs of genital TB, yet the signs may not be seen in the early stages of tuberculosis, performing an endometrial curettage while at it reduces the need for multiple invasive procedures and provide with confirmatory diagnosis. As CBNAAT has been authorized by RNTCP for diagnosis pulmonary TB and other extra pulmonary tuberculosis, its relevance in diagnosis of female genital tuberculosis requires to be researched further.

1.1 WHO Guidelines for EPTB

Diagnosis of EPTB should be done with following the criteria along with evidence of active EPTB: [3]

1. Culture-positive specimen OR
2. Positive histology OR
3. Positive clinical proof consistent

X-ray chest, tuberculin skin test (TST), erythrocyte sedimentation rate (ESR), and blood count tests to rule out a Tuberculi focus elsewhere in the body with a proper clinical examination. Hysterosalpingography (HSG) and ultrasonography (USG) are two imaging procedures that can be used to diagnose FGTB [7]. HSG focuses on the internal structure of the female genital canal as well as tubal patency, whereas ultrasonography assesses ovarian, uterine, and extra pelvic involvement all at once [8]. The laparoscopic findings may range from a normal appearance to tubercles on the surface, fimbrial tubal block, beaded appearance of fallopian tubes, peri-tubal adhesions, peri-ovarian adhesions, tubo-ovarian mass, hydrosalpinx, and stiff tubes.

The specimen's histopathology describes probable Tuberculosis infection characteristics, as well as granulomatous caseous lesions. Tuberculosis is depicted by the presence of classic caseous with granulomas and giant epithelioid cells; however, these lesions can also be seen in fungal illnesses, systemic lupus erythematosus, syphilis, leprosy, rheumatoid arthritis, pneumoconiosis, and sarcoidosis.

The luteal phase of the menstrual cycle [day 20-25] is the most accurate period for endometrial sampling which is required for the diagnosis of large cells and tubercles.

Acid fast bacilli smear staining of endometrial tissue is a quick test that requires only 10 organisms per millimeter to be positive.

The minimum time to positive in Lowenstein-Jensen medium cultures is 4-8 weeks. When endometrial samples were analyzed, Thangappah et al. [6] found that AFB smear positive results and culture positive results were 8.3 percent and 5.2 percent, respectively, among the 72 infertile women studied. The positive effect in LJ medium and BACTEC for premenstrual symptoms was demonstrated by Goel et al. The proportions of the samples were 1.83 percent and 8.8 percent, respectively [9].

PCR is a fast molecular method for demonstrating nucleic-acid amplification

sequences unique to Mycobacteria tuberculosis and other various mycobacteria in people with FGTB. PCR tests take 8-12 hours to complete and can identify 10 bacilli/ml, even dead bacilli [10]. Although PCR has a higher sensitivity than micro-culture and histopathological report, and its specificity in diagnosing FGTB can be as high as 100 percent, it also produces false positive results, thus it cannot be used alone. Methods for diagnosing tuberculosis have been well researched and are currently in use. Nucleic-acid amplification tests (NAAT) give results in a few hours, as established in the literature with the use of amplification equipment [11].

The diagnosis of genital TB necessitates a high level of suspicion as well as a multimodal inquiry technique. Despite numerous technological advancements, the issue of catching this age-old disease persists.

In this study, we want to see how effective the CBNAAT molecular approach is at diagnosing genital TB in subfertile women who visit the Acharya Vinoba Bhave Rural Hospital's infertility clinic.

Research question: Is Cartridge Based Nucleic Acid Amplification Test [CBNAAT] better diagnostic modality as compared to other test available for FGTB?

Population: subfertile women of rural hospital

Intervention: Cartridge Based Nucleic Acid Amplification Test [CBNAAT]

Comparison: with other available diagnostic modalities

Outcome: Positive cases with CBNAAT

Hypothesis: CBNAAT has better sensitivity and specificity in diagnosing extrapulmonary genital TB.

2. AIM

This study aimed to evaluate the role of CBNAAT a molecular test in diagnosing genital TB amongst subfertile women of the rural hospital.

3. OBJECTIVES

1. To conduct Cartridge based nucleic acid amplification test CBNAAT test in subfertile women attending infertility clinic.

2. To conduct detailed clinical examination and perform other routine investigations for diagnosing genital tuberculosis.
3. To analyze positivity of CBNAAT in selected population.

4. METHODOLOGY

4.1 Study Design and Population

An **prospective, observational tertiary care center based study** will be conducted on sample size of population of **100 subfertile** who meets inclusion and exclusion criteria of this study after a elaborate history and clinical examination all patients will undergo investigations including pelvic sonogram, histopathological study, and CBNAAT at Wardha test tube baby center at AVBRH,sawangi.

4.2 Inclusion Criteria

- 1.All the consecutive women visiting infertility clinic and willing to undergo endometrial biopsy.
- 2.Women with unexplained infertility.

4.3 Exclusion Criterion

Women experiencing infertility due to following causes-

1. Infertility due to sexual disorders.
2. Infertility due to proven anovulation in previous cycles.
3. Infertility due to endocrine dysfunction.
4. previous history of pelvic surgeries.
5. Proven history of endometriosis.
6. Infertility due to male factors only.

Patients will undergo routine tests (CBC, ESR, TST), after which endometrial tissue samples will be collected aseptically and mounted for AFB smear, histopathological examination, and CBNAAT, a cartridge-based nucleic acid amplification test that detects Tuberculous bacilli as well as testing for Rifampicin resistance. It's simple, quick, and inexpensive, and it doesn't require any technological expertise. Due to the use of disposable closed cartridges that prevent cross contamination, it may detect tuberculosis in under two hours and deliver accurate results. TST is employed in areas with low resources for cultural facilities.

After collecting and analyzing the data, the diagnostic tests used, such as pelvic USG,

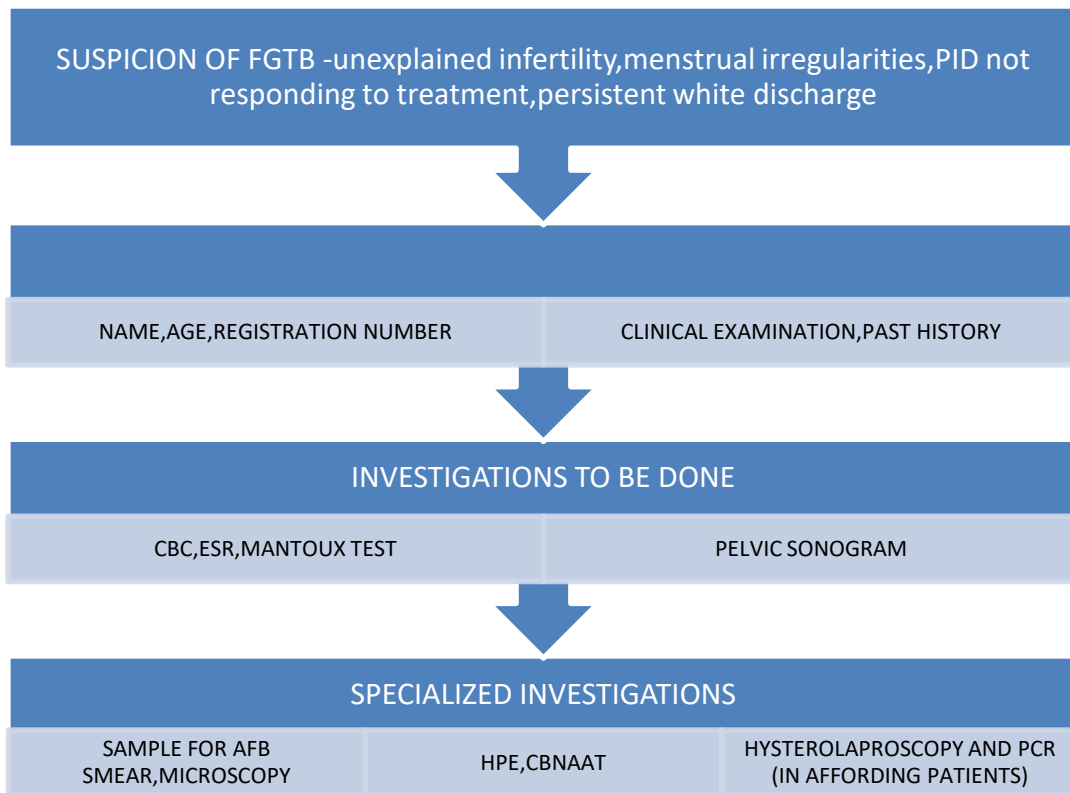


Fig. 1. Flowchart of methodology

histopathologic examination, and CBNAAT positivity, as well as laparoscopy and PCR of endometrial aspirate for patients who can afford it, will be compared for accurately diagnosing female genital tuberculosis [FGTB] by calculating sensitivity, specificity, positive predictive value, and negative predictive value; after that, these modalities will be compared for accurately diagnosis.

On basis of which reliability and accuracy of the tests will be observed.

The study site was a rural based tertiary care institute, which caters to about 300-400 patients with infertility each year. The incidence of FG TB (Female Genital Tract Tuberculosis) in the geographic region of study site varies in ranges from 1–19 % in various parts of India [7,12]. Considering the incidence of 4% and by using the value of $Z_{1-\alpha/2}$ as 1.96 at 10% type I error, the sample size was calculated using the following formula:

$$\frac{Z_{1-\alpha/2}^2 p(1 - p)}{d^2}$$

p= 4% = 0.4

1-p = 1- 0.4= 0.6

d = desired margin of error = 10% = 0.1

$$N = \frac{1.96^2 0.4 (1 - 0.4)}{0.1^2} = 92.19$$

Using 10% attrition rate, 100 = (92 + 10% of 92) subjects were included in the study.

Software to be used SPSS 22.0 Version, GraphPad Prism 7.0 Ver

Statistical analysis to be done -sensitivity, specificity, negative predictive value, positive predictive value.

Study design: Prospective observational study

Power of the test :80%

Level of significance :5%

4.4 Expected Outcome

The diagnostic value of CBNAAT in detection of female genital tuberculosis seems to be limited, although it has a high positive predictive value.

The various diagnostic modalities for genital tuberculosis available for genital tuberculosis, will be compared with diagnostic value of CBNAAT.

Cartridge Based Nucleic Acid Amplification Test is an easy, cost effective and quite accurate and rapid test for detection of tuberculosis especially Pulmonary Tuberculosis. Hence, it's use for detection of genital Tuberculosis might prove beneficial. This study aims to establish whether Cartridge Based Nucleic Acid Amplification Test has better sensitivity and specificity in diagnosing extrapulmonary genital Tuberculosis as compared to other conventional diagnostic tests.

5. CONCLUSION

Conclusion will be drawn after statistical analysis.

6. SCOPE, LIMITATIONS, IMPLICATIONS

Despite Anti tubercular treatment, the majority of females acquire vaginal tuberculosis, which leads to infertility. The conception rate for such women is low (19.2%), and the live birth rate is much lower (7%). The sole therapeutic option left for such women is Intra uterine insemination and embryo transfer [IVF-ET] in females whose endometrium has not been affected and has a pregnancy rate of 16.6% in every embryo transfer. If patient's fallopian tubes are damaged even after ATT, but the endometrium of the uterus responds to treatment and they have no endometrial adhesions or mild adhesions that may be removed hysteroscopically, IVF -ET is recommended. If they have endometrial TB, which destroys the endometrium and causes microscopic capillaries of the uterus to shrivel, they should consider surrogacy or adoption.

CONSENT AND ETHICAL APPROVAL

The procedure will only be done after obtaining informed written consent from the participants and the study adheres to STROBE guidelines.

COMPETING INTERESTS

Authors have declared that no competing interests exist.

REFERENCES

1. Golden MP, Vikram HR. Extrapulmonary tuberculosis: An overview. *AFP*. 2005;72(9):1761–8.
2. Ramakant B. Indian scientists developing diagnostic algorithm for female genital TB [Internet]; 2014.
3. Grace GA, Devaleenal DB, Natrajan M. Genital tuberculosis in females. *Indian J Med Res*. 2017;145(4):425–36.
4. Schaefer G. Female genital tuberculosis. *Clin Obstet Gynecol*. 1976;19(1):223–39.
5. Chauhan LS. Drug resistant TB--RNTCP response; 2008
6. Thangappah RBP, Paramasivan C, Narayanan S. Evaluating PCR, culture & Histopathology in the diagnosis of female genital tuberculosis. *Indian Journal of Medical Research*. 2011;134(1): 40–40.
7. Sharma JB. Current diagnosis and management of female genital tuberculosis. *J Obstet Gynaecol India*. 2015;65(6):362–71.
8. Shah HU, Sannananja B, Baheti AD, Udare AS, Badhe PV. Hysterosalpingography and ultrasonography findings of female genital tuberculosis. *Diagn Interv Radiol*. 2015;21(1):10–5.
9. Goel G, Khatuja R, Radhakrishnan G, Agarwal R, Agarwal S, Kaur I. Role of newer methods of diagnosing genital tuberculosis in infertile women. *Indian Journal of Pathology and Microbiology*. 2013;56(2):155.
10. Neonakis IK, Spandidos DA, Petinaki E. Female genital tuberculosis: A review. *Scand J Infect Dis*. 2011;43(8):564–72.
11. Singh M, Sethi GR, Mantan M, Khanna A, Hanif M. Cartridge based nucleic acid amplification test (CBNAAT) For the diagnosis of pulmonary tuberculosis in children. In *D107. Tuberculosis Infection and Disease: Epidemiology and Diagnosis*. American Thoracic. 2016;A7695-A7695. Society.
12. Gupta N, Sharma JB, Mittal S, Singh N, Misra R, Kukreja M. Genital tuberculosis in Indian infertility patients. *Int J Gynaecol Obstet*. 2007;97(2):135–8.

© 2021 Deo et al.; This is an Open Access article distributed under the terms of the Creative Commons Attribution License (<http://creativecommons.org/licenses/by/4.0>), which permits unrestricted use, distribution, and reproduction in any medium, provided the original work is properly cited.

Peer-review history:
The peer review history for this paper can be accessed here:
<https://www.sdiarticle5.com/review-history/81649>